

Flexible Endoscopic Treatment of Zenker's Diverticulum: A Center Experience and Literature Review

I. Radouane^{a*} and R. Akka^a

^a *Department of Gastroenterology, Avicenne Military Hospital, Marrakech, Morocco.*

Authors' contributions

This work was carried out in collaboration among all authors. All authors read and approved the final manuscript.

Article Information

Open Peer Review History:

This journal follows the Advanced Open Peer Review policy. Identity of the Reviewers, Editor(s) and additional Reviewers, peer review comments, different versions of the manuscript, comments of the editors, etc are available here: <https://www.sdiarticle5.com/review-history/101526>

Case Study

Received: 10/04/2023

Accepted: 13/06/2023

Published: 19/06/2023

ABSTRACT

Zenker's pharyngo-oesophageal diverticulum is a rare acquired hernia of the posterior mucosa at the pharyngo-oesophageal junction. The pathophysiology of this condition is still poorly understood. Our article aims to shed light on the epidemiological, clinical, paraclinical and therapeutic aspects of this pathology.

By adopting a retrospective study, we followed 3 patients with Zenker's diverticulum, between January 2019 and December 2022, in our department of Hepato-gastro-enterology.

They were 3 men aged 58, 54 and 90 years with a median age of 67.3 years.

The clinical symptoms observed were dominated by upper dysphagia and regurgitation in all cases (100%). One patient had also weight loss as a complication (33%).

The endoscopic examination combined with the cervico-thoracic CT scan allowed the diagnosis in all our patients (100%), with an average size of 3.5 cm (1.5-4 cm) for the diverticulum.

The treatment adopted for our 3 patients was endoscopic diverticulotomy performed with a diverticuloscope. . The procedure duration was 35+/- 5 minutes with simple aftercare.

The patients resumed oral feeding the next day, despite minimal postoperative pain. The median hospitalisation duration was 2 days and the average follow-up time was 12 months. Clinical success was 100% and no complications were noted.

*Corresponding author: Email: imanageradou16@gmail.com;

In conclusion, endoscopic diverticulotomy is an effective treatment to quickly improve symptoms while reducing hospitalization length and complications risk, especially in elderly patients with comorbidities.

Keywords: Zenker's diverticulum; flexible endoscopic treatment; efficacy.

1. INTRODUCTION

Pharyngo-oesophageal diverticula are uncommon, but the most common is Zenker's diverticulum, which is an acquired hernia of the posterior mucosa of the pharyngo-oesophageal junction forming at Killian's triangle, a zone of weakness between the crico-pharyngeal muscles and the thyro-pharyngeal muscle.

Symptoms include upper dysphagia, regurgitation and sometimes it could lead progressively to weight loss and other respiratory complication.

Treatment is either surgical, combining diverticulectomy or diverticulopexy with myotomy of the cricopharyngeal muscle, or endoscopic, with an oesophago-diverticulostomy.

The level of evidence for the superiority of endoscopic techniques (rigid or flexible) versus open surgery for the treatment of Zenker's diverticulum is limited and controversial given the data currently available [3].

Through this retrospective study, carried out in the Hepato-Gastroenterology Department at our hospital, and through a recent review of the literature, we attempt to assess the epidemiological, etiopathogenic, clinical and paraclinical aspects of this pathology, as well as the therapeutic and evolutionary data, in order to judge the success or failure of endoscopic treatment.

2. MATERIELS AND METHODS

This is a retrospective descriptive study of a series of 3 patients with Zenker's diverticulum.

Our study was carried out in the Gastroenterology Department of the Avicenne Military Hospital as first experience. It was spread over a period of four years from 1 January 2019 to 31 December 2022.

Patients were identified from the hospitalisation register of the Gastroenterology Department.

Clinical, para-clinical, therapeutic and evolutionary data were recorded on a pre-established data sheet (Appendix 1), then collected from the medical records of the Gastroenterology Department.

3. OBSERVATION NO 1

Mr M. E. aged 58, with a history of chronic smoking at a rate of 30 PA, hospitalised in February 2019 (27/02/19 - 29/02/2019 i.e. 2 days) in the gastroenterology department for dysphagia. He complained of upper dysphagia to solids evolving for 1 year of progressive worsening associated with regurgitation and significant weight loss not quantified.

Clinical examination on admission revealed a patient in good general condition with slightly discoloured conjunctivae and no palpable cervical mass.

The diagnosis was made by oeso-gastro-duodenal fibroscopy (Figs. 1-2) and a cervico-thoracic CT scan, which showed a 4 cm formation of mixed content with hydro-aeric content in the cervical retrooesophagus, suggestive of a Zenker diverticulum.

The operation was performed under general anaesthetic. After exposing the diverticulum with a flexible COOK diverticuloscope (Fig. 3), using a guide wire to locate the oesophageal lumen (Fig. 4), the diverticulotomy was performed using an Olympus electrosurgical knife for submucosal dissection with a triangular head (Fig. 5) connected to a BOWA 300 scalpel in GASTROKNIFE effect 3 mode. Three metal clips (Fig. 6) were then placed on the edges of the diverticulotomy at the end of the procedure. The procedure lasted 40 minutes, and the immediate after-effects were straightforward, with the patient being able to resume eating the following day despite minimal post-operative pain.

The patient was seen in consultation at 1 month, 3 months, 6 months and 1 year after the operation, with a favourable outcome and no recurrence.

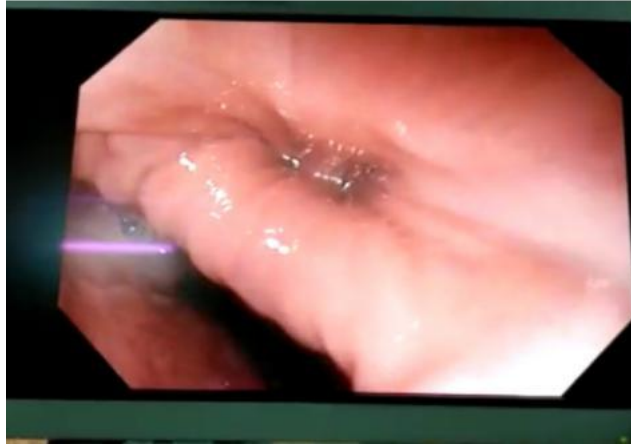

Fig. 1. Global endoscopic view of Zenker's diverticulum

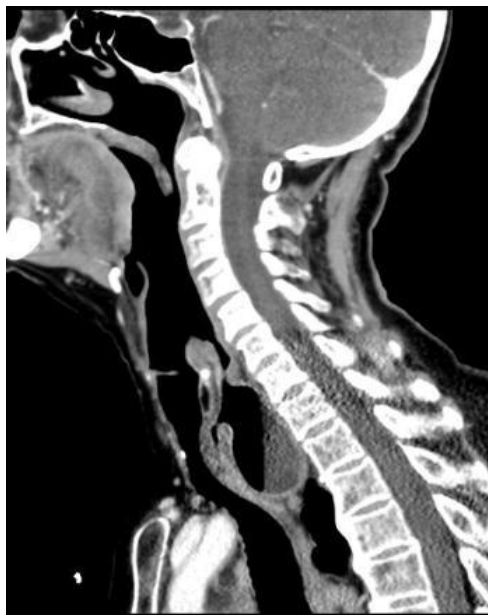

Fig. 2. Cervico-thoracic CT scan showing a cervical retroesophageal mixed content formation suggestive of a Zenker diverticulum on a sagittal section

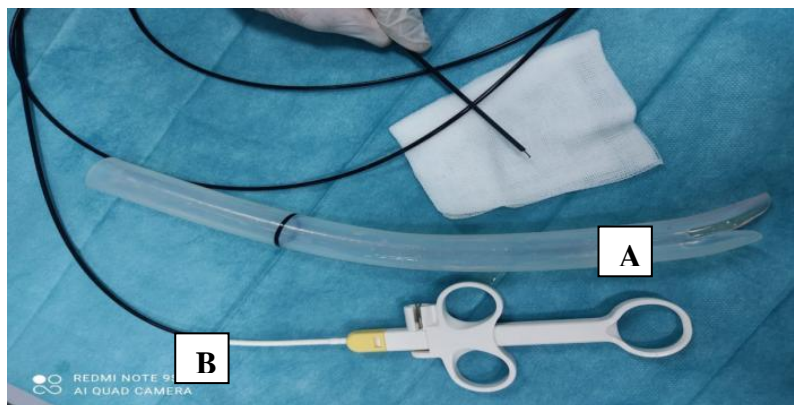

Fig. 3. Diverticulotomy material

*A: Cook brand flexible diverticuloscope with long and short tips.
B: Sub-mucosal dissection knife.*

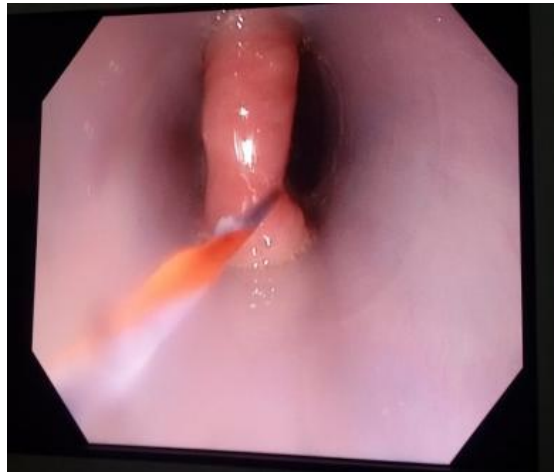

Fig. 4. Guide wire marking the oesophageal lumen

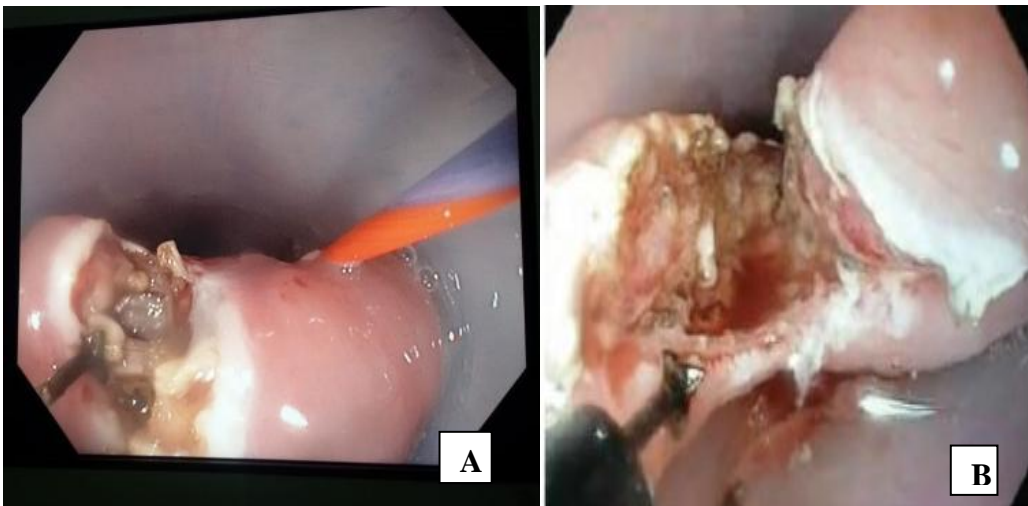


Fig. 5(A+B). Dissection using a triangular electrosurgical knife

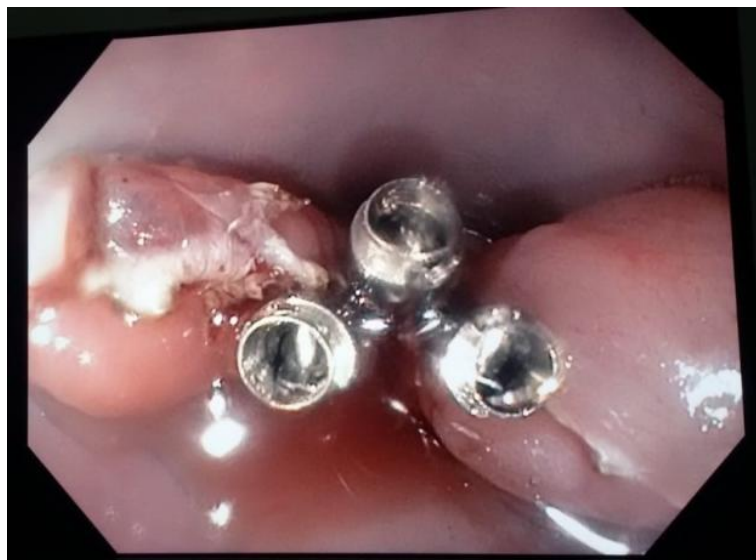

Fig. 6. Metal clips fitted after diverticulotomy

4. OBSERVATION NO 2

Mr T. L. aged 54, with the following history: treated for acid reflux for 6 years, known chronic smoker with 24 PA weaned 6 years ago, hospitalised in October 2021 (from 13/10/21 - 15/10/21 i.e. 2 days) in the gastroenterology department for dysphagia. He

complained of dysphagia with solids, which then became mixed and had been progressively worsening for 2 years, associated with regurgitation.

Clinical examination on admission revealed a patient in good general condition with no abnormalities.

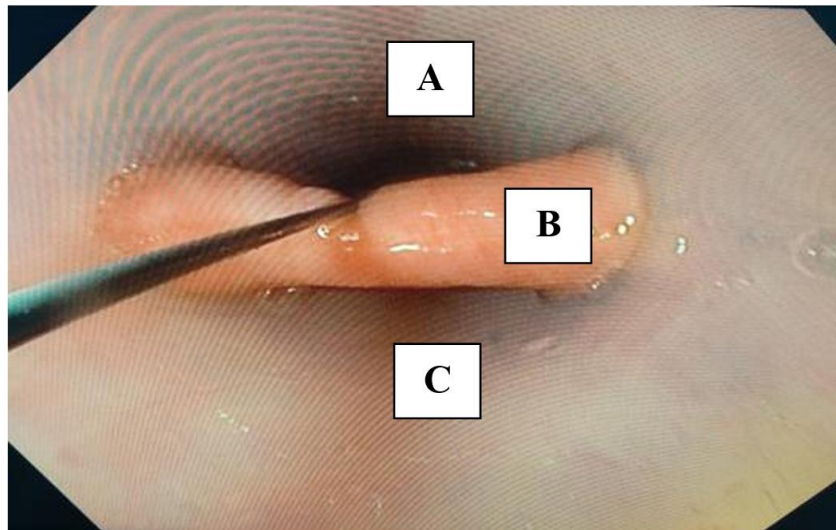


Fig. 7. Endoscopic view of Zenker's diverticulum: FOGD performed at the gastroenterology department of HMA marrakech

A: Orifice of the oesophagus B: Septum of the crico-pharyngeal muscle C: Zenker's diverticulum DZ

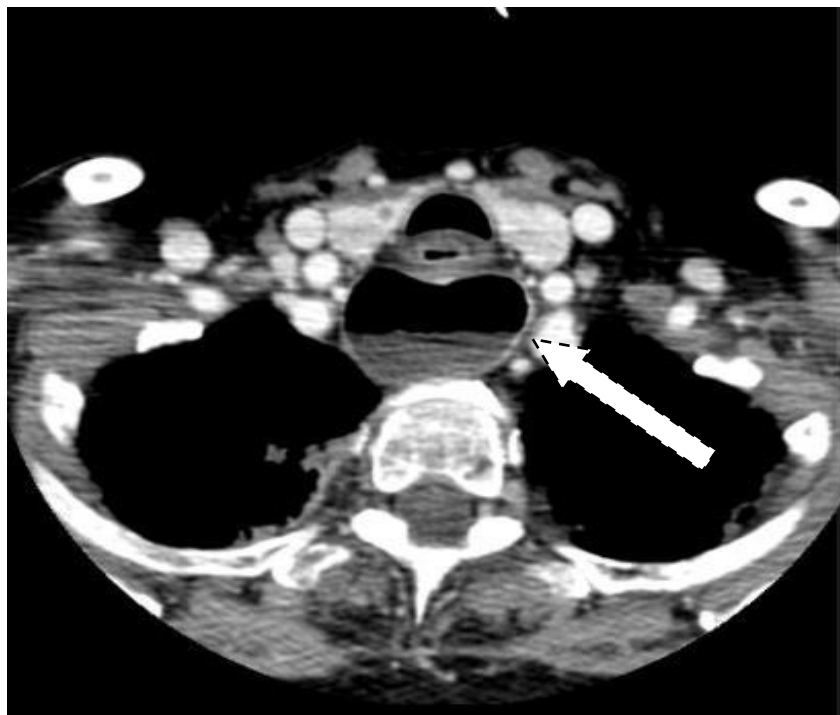


Fig. 8. Cervico-thoracic CT scan showing a 3.5 cm cervical retrooesophageal mixed content formation suggestive of Zenker's diverticulum on axial section

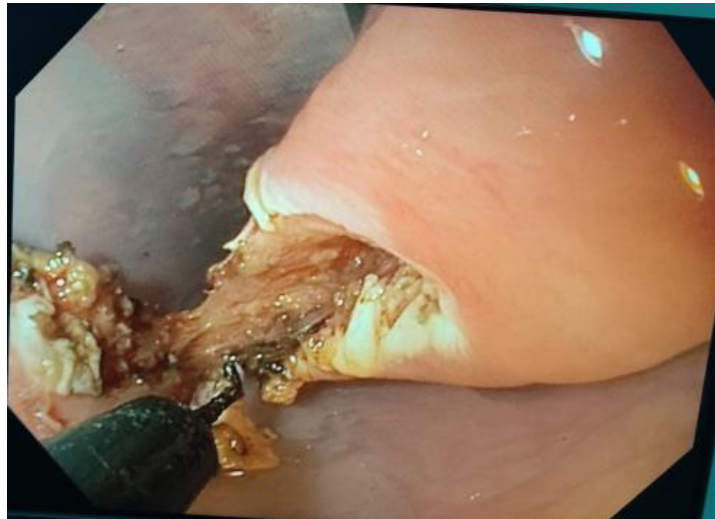

Fig. 9. Dissection with an electro-surgical hook knife

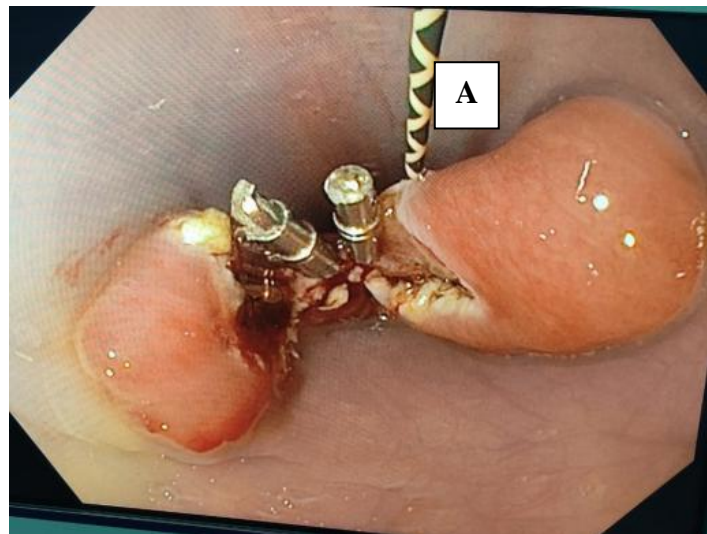


Fig. 10. Metal clips applied after diverticulotomy
A: Guide wire marking the oesophageal lumen

The diagnosis was made by oeso-gastro-duodenal fibroscopy (Fig. 7) and a cervico-thoracic CT scan (Fig. 9) which showed a 3.5cm mixed content formation with cervical retro oesophageal hydro-aeric content suggestive of a Zenker diverticulum.

The operation was performed under general anaesthetic and with the same procedure for all the patients.

The patient was seen in consultation at 1, 3 and 6 months after the procedure, with a favourable outcome and no recurrence.

5. OBSERVATION NO 3

Mr B.B. aged 90 years, with a history of hypertension for 5 years under treatment with good compliance and operated in 1995 for cholecystectomy, hospitalised in May 2022 (from 18/05/22 to 20/05/22 i.e. 2 days) in the gastroenterology department for upper dysphagia. The patient complained of high dysphagia with solids and then mixed dysphagia, which had been progressively worsening for 2 years, associated with regurgitation.

Clinical examination on admission revealed a patient in good general condition with no abnormalities.

The diagnosis was made by oesogastro-duodenal fibroscopy alone (Fig. 11) showing an odiverticulum separated from the oesophageal orifice by the crico-pharyngeal septum.

The operation was performed under general anaesthetic and with the same procedure for all the patients (Fig. 12). The patient was seen in

consultation at 1 month and 3 months after the procedure, with a favourable outcome and no recurrence.

Table 1 summarises the clinical features reported, the additional examinations carried out, the surgical procedure performed, the post-operative follow-up and the characteristics of the diverticulum.

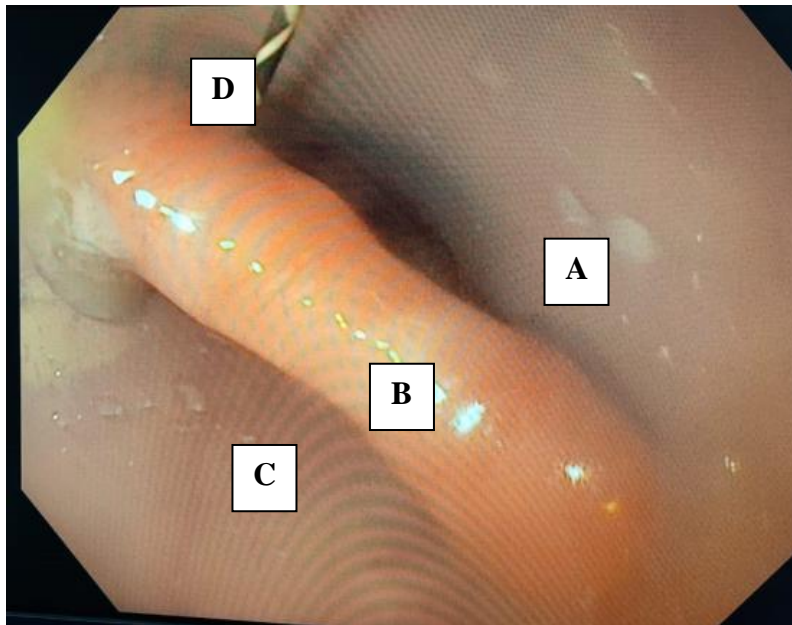


Fig. 11. Endoscopic view of Zenker's diverticulum
A: Orifice of the oesophagus B: Septum of the crico-pharyngeal muscle
C: Zenker Diverticulum DZ D: Guide wire

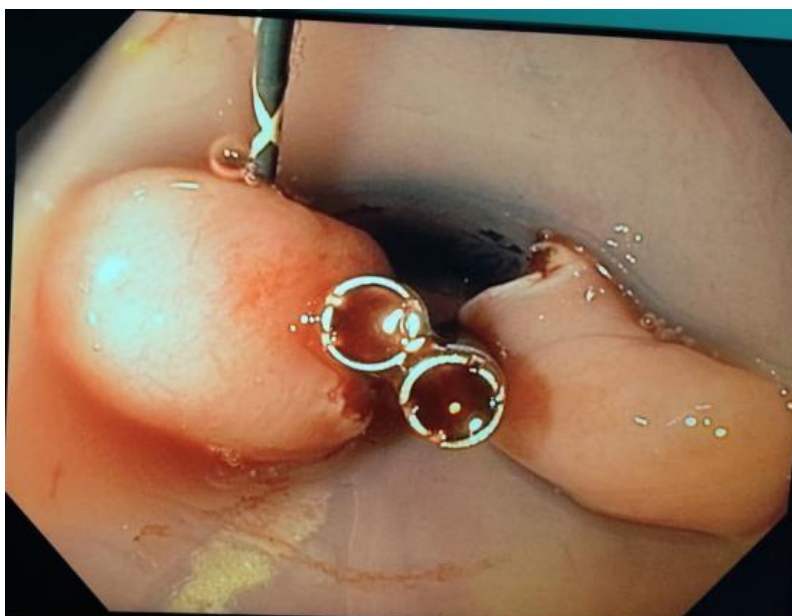

Fig. 12. Metal clips on the edges of the diverticulotomy

Table 1. Clinical features, paraclinical examinations, techniques and Postoperative follow-up

N°	Age	Sex	Functional signs	Complications	Complementary examinations	Surgical technique	Postoperative follow-up	Length of hospital stay	Size
1	58	M	Upper dysphagia + regurgitation	Weight loss not quantified	Fibroscopy + CERVICO-THORACIC CT	Diverticulotomy by electro-surgical knife by ES	Simples	2 days	4 cm
2	54	M	Upper dysphagia + regurgitation + RGO	Aucune	Fibroscopy + CERVICO-THORACIC CT	Diverticulotomy by electro-surgical knife by ES	Simples	2 days	3.5 cm
3	90	M	Upper dysphagia + regurgitation + RGO	Aucune	Fibroscopy + CERVICO-THORACIC CT	Diverticulotomy by electro-surgical knife by ES	Simples	2 days	1.5 cm

6. DISCUSSION

Zenker's diverticulum is relatively a rare condition, with an overall prevalence of between 0.01% and 0.11%, and occurs most frequently in males between the seventh and eighth decades of life [1].

The pathophysiology is uncertain and not completely understood. However, it involves the pharyngeal and crico-pharyngeal muscles which, by responding inadequately to swallowing, create abnormally high pressure in the pharynx leading to the formation of a mucosal hernia through a zone of pharyngeal-oesophageal fabrae [2-3].

Dysphagia is the predominant symptom in ZD, but the specificity of this disease is its association with non-acidic regurgitation of food ingested several hours previously, which can be nauseating and therefore cause halitosis. It is above all responsible for respiratory complications dominated by false routes and inhalation pneumopathy or, to a lesser degree of severity, an irritative cough. These complications may be the means by which the disease is revealed [4].

The diagnosis of ZD in our series was made by CT scan and endoscopy. However, in literature we find that fluoroscopic evaluation of swallowing is the reference examination recommended by the ESGE [5-6]. Even if the diagnosis can be made by endoscopy and cross-sectional imaging, because this examination allows dynamic visualisation at different stages of swallowing, with the added advantage of assessing the dimensions of the diverticular sac, looking for differential diagnoses (oesophageal stenosis, an oesophageal motor disorder or even gastro-oesophageal reflux) and also to identify micro-inhalations.

Treatment is indicated when the diverticulum is symptomatic. There are currently three main treatment options for ZD [4]:

- Open transcervical surgery, allowing diverticulectomy or diverticulopexy, both of which are systematically associated with myotomy of the crico-pharyngeal muscle.
- Rigid endoscopic septotomy: endoscopic stapling or CO₂ laser treatment to section the septum of the cricopharyngeal muscle to create a common cavity between the diverticulum and the oesophageal lumen.

- Flexible or soft endoscopic septotomy, based on the same principle as rigid endoscopy, without being limited by the patient's anatomical constraints.

The endoscope is initially inserted as a guide, and then the diverticuloscope (Fig. 3) is slid through, so that the smaller valve is in the diverticulum and the longer one in the oesophagus.

The wall between the oesophagus and the diverticulum will be exposed in the centre of the diverticuloscope when the endoscope is removed.

Once the wall between the diverticulum and the oesophagus has been exposed, the second step is to section this wall and the cricopharyngeal muscularis: this is the diverticulotomy.

The wall between the diverticulum and the oesophagus is sectioned to perform the myotomy of the cricopharyngeal muscle. The dissection must be carried out under constant visual control; it must not be pushed too far downwards to avoid the risk of the perforation extending into the mediastinum. Section should therefore be limited to 5 minutes from the bottom of the diverticulum.

Diverticulotomy can be performed by several methods: scalpels, coagulating forceps, argon plasma. Although there is no proof that one method is superior to the other, precutting needles and especially knives undoubtedly allow finer and safer dissection of the muscular fibres, whereas argon plasma, which chars the dissection plane, seems less attractive.

There are no prospective comparative studies between surgical treatment (open approach or rigid endoscopy) and flexible endoscopic treatment.

Two major systematic reviews and meta-analyses involving 3079 and 596 patients concluded that the clinical success rates were significantly different in favour of open surgery, i.e. 94-96% compared with 82-87% with the endoscopic approach [7-8] but at the price of a complication rate significantly unfavourable to open surgery, i.e. 11-15% compared with 7-9% with endoscopic treatment.

In our 3 cases, we had a rate success of 100% with no complications. Most of the relevant data on the efficacy and safety of flexible endoscopic

septotomy for the treatment of Zenker's diverticulum are summarised in the meta-analysis by Ishaq et al. [9], which included 813 patients, had a success rate of 91% with an adverse event rate of 11.3% and a recurrence rate of 11%.

Since 2020, flexible endoscopic septotomy has been recommended as first-line treatment by the ESGE, regardless of the size of the diverticulum [9].

With the advent of subdissection and tunneling techniques such as oesophageal PEOM, new alternative strategies for the treatment of Zenker's diverticulum by flexible endoscopy are emerging, the most promising being Z-POEM first described in 2016 by Li et al. [10].

Yang et al. collected retrospective data on 75 patients treated with Z-PEOM in 10 centres and found a technical success rate of 97%, a complication rate of 6.7%, all managed conservatively, a clinical success rate of 92% and only one symptomatic recurrence after a median follow-up of 10 months [11].

A large retrospective multicentre study (12 centres) compared flexible and rigid endoscopic septotomy with Z-POEM in 245 patients treated consecutively between January 2016 and September 2019, i.e. 119 Z-POEMs, 86 flexible septotomies and 40 rigid septotomies. Clinical success was in favour of Z-POEM but was not significant at 92.7% compared with 89.2% for rigid septotomy and 86.7% for flexible septotomy. The rate of symptomatic recurrence was unfavourable to Z-POEM, but also non-significant, at 14.7% compared with 9.2% and 9.1% respectively for flexible and rigid septotomy. The complication rate was 30% for patients undergoing rigid septotomy, 16.8% for patients undergoing Z-POEM and 2.3% for patients undergoing flexible septotomy ($P < 0.05$) [12]. This rate of recurrence in the case of Z-POEM is surprising compared with the rest of the literature, but may potentially be explained by the fact that the mucosal pouch of the diverticulum is left in place; however, this remains perfectly treatable by performing a complementary flexible endoscopic septotomy [13].

The largest study reported to date favours flexible endoscopic septotomy [12]. Z-POEM is not recommended by ESGE except in the context of studies [4], which will therefore be

necessary to define its role in the management of DZ.

7. CONCLUSION

Treatment of Zenker's diverticulum by flexible endoscopy consists of performing a diverticulotomy sectioning the cricopharyngeal muscle. A diverticuloscope is required to ensure good exposure of the diverticulum and safe dissection.

The endoscopic approach allows rapid improvement in symptoms, with a reduction in the length of hospital stay and the risk of complications. It is particularly preferred in elderly patients suffering from a number of pathologies.

Although Z-POEM is of great interest in the management of incipient ZD [14] and is a priori the best technique in the event of failure of a first treatment [15].

CONSENT

As per international standard or university standard, patient(s) written consent has been collected and preserved by the author(s).

ETHICS APPROVAL

This work was performed following the code of ethics under the supervision of our institution's medical and ethics committee.

COMPETING INTERESTS

Authors have declared that no competing interests exist.

REFERENCES

1. Maran AGD, Wilson JA, Muhanna AHA. Pharyngeal diverticula. Clin Otolaryngology Allied Sci. 1986;11:219-25.
2. Fulp SR, Castell DO. Manometric aspects of Zenker's diverticulum. Hepatogastroenterology. 1992;39(2):123-126.
3. Cook IJ, Gabb M, Panagopoulos V, et al. Pharyngeal (Zenker's) diverticulum is a disorder of the upper esophageal sphincter opening. Gastroenterology. 1995;103(4):1229-1235.

4. Hepato-gastro-oncologie digestive. *Fevrier*. 2023;30(2).
5. Jaffer NM, Ng E, Au FW-F, et al. Fluoroscopic evaluation of oropharyngeal dysphagia: Anatomic, technical, and common etiologic factors. *Am J Roentgenol*. 2015;204:49-58.
6. Weusten B, Barret M, Bredenoord A, et al. Endoscopic management of gastrointestinal motility disorders - part 2 : European Society of Gastrointestinal Endoscopy (ESGE) Guideline. *Endoscopy* 2020;52:600-14.
7. Verdonck J, Morton RP. Systematic review on treatment of Zenker's diverticulum. *Eur Arch Oto-rhino*. 2015;272:3095-107.
8. Albers DV, Kondo A, Bernardo WM, et al. Endoscopic versus surgical approach in the treatment of Zenker's diverticulum: Systematic review and meta-analysis. *Endosc Int Open* 2016;4:E678-86.
9. Ishaq S, Hassan C, Antonello A, Tanner K, Bellisario C, Battaglia G, Anderloni A, Correale L, Sharma P, Baron TH, Repici A, Flexible endoscopic treatment for Zenker's diverticulum: A systematic review and meta-analysis. *Gastrointestinal Endoscopy*; 2016. DOI: 10.1016/j.gie.2016.01.039
10. Li QL, Chen WF, Zhang XC, et al. Submucosal tunneling endoscopic septum division: A novel technique for treating Zenker's diverticulum. *Gastroenterology*. 2016;151:1071-4.
11. Yang J, Novak S, Ujiki M, et al. An international study on the use of peroral endoscopic myotomy in the management of Zenker's diverticulum. *Gastrointest Endosc*. 2020;91:163-8.
12. Ghamdi SSA, Farha J, Moran RA, et al. Zenker's peroral endoscopic myotomy, or flexible or rigid septotomy for Zenker's diverticulum: A multicenter retrospective comparison. *Endoscopy*. 2022;54:345-51.
13. Lambin T, Lafeuille P, Rivory J, et al. When Z-POEM comes to the rescue of classical diverticulotomy and vice versa. *Endoscopy*. 2022;54:E193-4.
14. Lupu A, Yet C, Lafeuille P, et al. Zenker's diverticulum peroral endoscopic myotomy is effective in the case of an incipient Zenker's diverticulum. *Endoscopy*.
15. Sanaei O, Ichkhanian Y, Mondragón OVH, et al. Impact of prior treatment on feasibility and outcomes of Zenker's peroral endoscopic myotomy (Z-POEM).

APPENDIX 1: Operating sheet

Patient admission ticket:

I. Patient's identity:

- Surname and first name (initials):
- Sex: Male Female
- Age :
- Profession :
- Origin and place of residence :
- Date of entry: Date of exit :
- Telephone number:
- Mutualist:

II. Patient history:

- Personal:
 - Medical:
 - o hypertension
 - o Heart disease: Yes No If yes, which:.....
 - o Diabetes
 - o Dysthyroidism / Thyroid nodule or goitre
 - o GERD / HP gastritis
 - o Lung disease: Yes No If yes, which one:.....
 - o Neoplasia: Yes No If yes, which one:.....
 - o Other:
 - Surgical :
 - Toxico-allergic :
 - o Smoking: how many packets per day / duration / withdrawal
 - o Alcoholic
 - o Allergy
 - o Other

- Family:

III. Clinical data

1. Clinical signs (history of the disease):

- o Digestive signs:
 - Dysphagia: Yes No If yes specify: to solids to liquids Mixed High Low the duration of evolution :
 - Regurgitation: Yes No if yes specify:.....
- o General signs:
 - Asthenia: Yes No Not specified
 - Weight loss: Yes No Unspecified If yes, how long:
- o Extra-digestive signs:
 - Cough: Yes No if yes specify:.....
 - Chest pain: Yes No if yes specify:.....
 - Dysphonia: Yes No if yes specify:.....
 - Hypersialorrhea: Yes No if yes specify:.....
 - Other :

2. Clinical examination:

- General examination: - Vitals: HR: BP: FR: T°: Weight:
 - Nutritional status: - Hydration status
 - Conjunctiva :
- Cervical examination:
 - ✓ Inspection: Normal Left cervical swelling: Yes No
 - ✓ Palpation: Normal Left cervical mass: Yes No if yes specify: Consistency: Soft Hard
 - Dimensions in cm: Adhesion: in relation to superficial plane:..... and deep plane
 - ✓ Auscultation: Normal Hydro-aeric noises:
- Examination of lymph node areas:
- Abdominal examination:
- Pleuropulmonary examination:
- The rest of the physical examination:.....

3. Paraclinical data:

- Imaging:
 - Standard chest X-ray: No Yes Result:.....
 - Transit oeso-gastro-duodenal (TOGD): No Yes Result:.....
 - Cervico-thoracic CT scan: No Yes Result:.....
 - Other:
- Endoscopy:
 - Oeso-gastro-duodenal fibroscopy: No Yes Result (size ++):.....

4. Treatment and course:

- Surgical ttt: Yes No if yes specify :
 - Surgical technique :
 - Diverticulectomy + myotomy:
 - Diverticulopexy + myotomy:
 - Myotomy alone:
 - Duration of operation :
 - Duration of hospitalisation :
- Rigid endoscopic treatment: Yes No if yes specify:
 - Surgical technique:
 - *Laser CO2:
 - *Cutting with stapling:
 - *Other:
 - Duration of operation:
 - Length of hospital stay:
- Flexible endoscopic treatment: Yes No if yes specify:
 - Surgical technique:
 - *Argon plasma:
 - *Single-use forceps:
 - *Dissecting knife:
 - Duration of operation:
 - Hospital stay:
- Evolution after treatment:
 - Immediate:
 - Favourable:

Complications:

-Distant :

Favourable :

Complications:.....

▪ Follow-up:

rythm:

Success: Diet/Poids/Symptoms.....

Recurrence: Timeframe.....

© 2023 Radouane and Akka; This is an Open Access article distributed under the terms of the Creative Commons Attribution License (<http://creativecommons.org/licenses/by/4.0>), which permits unrestricted use, distribution, and reproduction in any medium, provided the original work is properly cited.

Peer-review history:

The peer review history for this paper can be accessed here:

<https://www.sdiarticle5.com/review-history/101526>