



Repair of an Inferior Canalicular Laceration using a Flexible Mono-Canalicular Probe with Self-Stabilizing Meatic Fixation

Mohcine El Mhadi ^{a*} and Aziz El Ouafi ^a

^a *Ophthalmology Department, Military Hospital Moulay Ismail, Meknes, Morocco.*

Authors' contributions

This work was carried out in collaboration between both. Both authors read and approved the final manuscript.

Article Information

DOI: 10.9734/OR/2023/v18i4393

Open Peer Review History:

This journal follows the Advanced Open Peer Review policy. Identity of the Reviewers, Editor(s) and additional Reviewers, peer review comments, different versions of the manuscript, comments of the editors, etc are available here: <https://www.sdiarticle5.com/review-history/104971>

Case Study

Received: 10/06/2023

Accepted: 15/08/2023

Published: 22/08/2023

ABSTRACT

Canalicular lacerations represent the first cause of intervention in lacrimal traumatology. They are observed in 16% of eyelid wounds and 20% of eyeball lesions. They can be caused by both penetrating and blunt trauma. Various materials have been used to stent the torn canaliculus in the past. Medical grade silicone, due to its inert nature and flexibility, has become the material of choice for tear stenting. We report the case of a lower canalicular laceration repaired using a flexible mono-canalicular probe with self-stabilizing meatic fixation, to describe the course of the intervention, as well as the advantages and tolerance of this technique. True mono-canalicular intubation, using a flexible mono-canalicular probe with self-stabilizing meatic fixation, has several advantages over other lacrimal intubation techniques. The placement of this probe is essential, to ensure the correct alignment of the anastomosis and the lacrimal lumen during the healing phase, to prevent fibrosis and stenosis after canalicular repair and thus to maintain permeability.

*Corresponding author: E-mail: Dr.mohcel@gmail.com;

Keywords: *Eyelids; lacrimal canaliculi; canalicular lacerations; mono-canalicular intubation; flexible mono-canalicular probe; self-stabilizing meatic fixation.*

1. INTRODUCTION

Canalicular lacerations represent the first cause of intervention in lacrimal traumatology. They are observed in 16% of eyelid wounds and 20% of eyeball lesions [1]. They can be caused by both penetrating and blunt trauma [1].

Various materials have been used to stent the torn canaliculus in the past. Medical grade silicone, due to its inert nature and flexibility, has become the material of choice for tear stenting [2–3].

True mono-canalicular intubation using a flexible mono-canalicular probe with self-stabilizing lacrimal fixation can constitute an easy alternative in the therapeutic arsenal in lacrimal traumatology [4–5].

We report the case of an inferior canalicular laceration repaired using a flexible mono-canalicular probe with self-stabilizing meatic fixation, to describe the course of the intervention, as well as the advantages and tolerance of this technique.

2. CASE PRESENTATION

A 19-year-old young man, with no particular history, admitted to the emergency department 4 hours after a fight, for a left inferior eyelid avulsion secondary to blunt trauma by punching.

On admission: the patient was hemodynamically stable, with no other associated lesions.

2.1 The Ophthalmological Examination Found

Avulsion of the medial canthus with a left lower palpebral wound associated with a frank section of the middle segment of the inferior lacrimal canaliculus passing 5 mm medial to the inferior meatus with identification of the internal end of the severed canaliculus as a pinkish-white tubular mucosal structure (Fig. 1, arrow). An upper and lower left eyelid bruise. The left eyeball is intact, with visual acuity at 20/20 (P2). The rest of the ophthalmological examination is unremarkable in both eyes.

2.2 Description of the Probe (Fig. 2)

The head of the probe alone secures the assembly. Entirely made of silicone, it looks like

an "ace of spades" in section, intended to be placed astride the punctum.

1. The flange, wider than the meatus, prevents its burial and intra-canalicular migration. This is the only visible part of the probe in place.
2. The neck is a narrower part, which connects the collar and the bulb.
3. The bulb lodges in the vertical segment of the canaliculus. It consists of two pyramids attached to the lower part of the neck. The orientation of the bases prevents externalization.
4. The silicone tube (0.64 mm in diameter and 15 cm in long), extends the bulb and a malleable metal mandrel completes the assembly.

2.3 Surgical Procedure

After topical anesthesia with 0.4% oxybuprocaine, wound cleansing with iodine polyvidone and local infiltration of 2% lidocaine with adrenaline.

An inferior canalicular sounding by Bowman probe number 1 was then used to pass through the two cut ends of the canaliculus and reach the lacrimal sac with obtaining a bone contact (which made it possible to measure the length of the mono-canalicular probe that will be used = 35 mm for our patient), then the punctum was dilated.

The external portion of the canaliculus is intubated by the mandrel through the meatus, up to the external part of the section where it will be retrieved and gently brought out, which will allow the progression of the probe until engagement of the head in the vertical portion of the canaliculus and the stable fixation of the flange on the punctum. The emerging silicone tube is cut 3.5 mm after the bulb of the probe and the rest of the latter is eliminated. Then, the internal part of the lacerated canaliculus is directly intubated. This is how a true mono-canalicular intubation (MCI) is performed (Fig. 3).

The two edges of the lacerated canaliculus were approximated using 2 transfixing stitches of 8-0 polyglactin. The wound of the canthus and the eyelid was then repaired with 7-0 polyglactin sutures for the deep plane and 6-0 for the superficial plane (Fig. 4).

The patient received topical treatment (3 months of lubricating eye drops and 7 days of antibiotic and corticosteroid eye drops) and oral treatment (8 days of antibiotics and 4 days of corticosteroids).

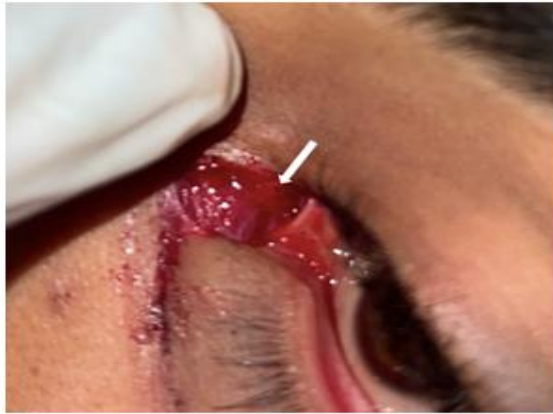

Fig. 1. Medial canthus avulsion with left inferior palpebral wound associated with frank section of the inferior lacrimal canaliculus middle segment, passing 5 mm medial to the inferior meatus, with identification of the internal end of the severed canaliculus (arrow) as a pinkish-white tubular mucosal structure

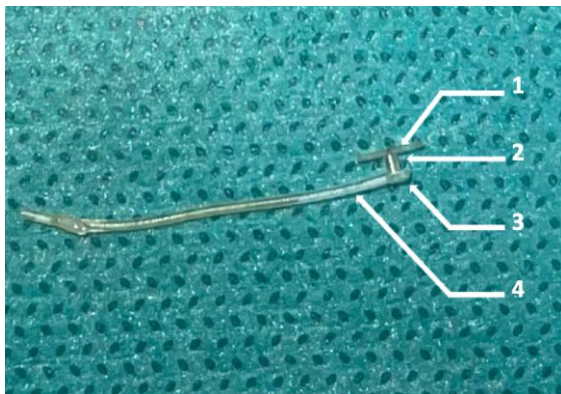


Fig. 2. 35 mm portion of the flexible mono-canalicular probe with self-stabilizing meatic fixation after elimination of the part containing the metal mandarin, with: 1- the flange, 2- the neck, 3- the bulb and 4- the silicone tube

The probe is left in place for 8 weeks. The control was carried out on the 2nd day, the 10th day (removal of the skin sutures, good tolerance of the probe which is stable), 4th week (good healing of the wound, good tolerance of the probe which is stable (Fig.5) and the 8th week (removal of the probe under topical anesthesia

by simple traction on the collar using forceps (Fig. 6), There is no lacrimation, bone contact is present, lacrimal ducts irrigation is permeable). 3 months later the result remains unchanged.

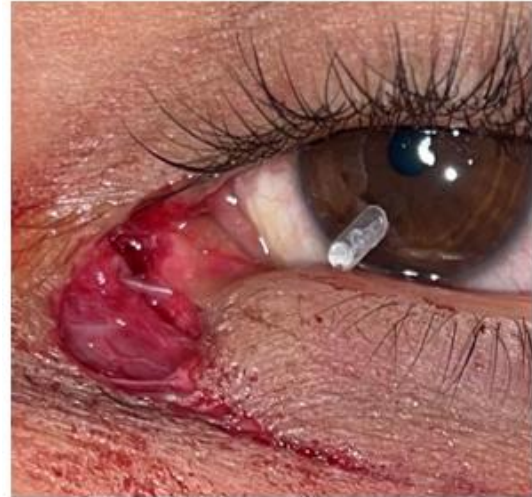

Fig. 3. True mono-canalicular intubation by positioning the flexible mono-canalicular probe, to ensure proper alignment of the anastomosis of the lacerated canaliculus two edges

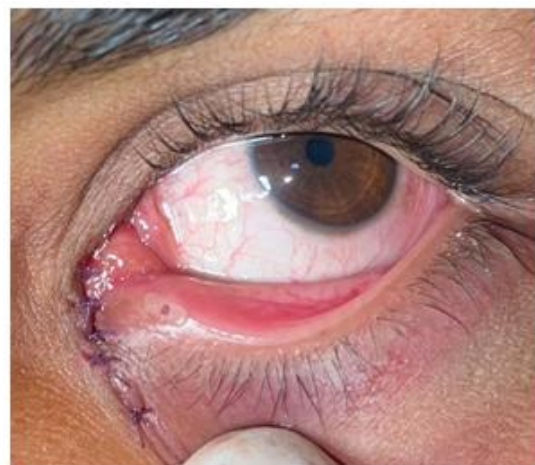

Fig. 4. Repair of the canthus and eyelid wound with polyglactin sutures (7-0 for the deep plane and 6-0 for the superficial plane). We note the stability of the probe by fixing the flange on the lower lacrimal punctum

3. DISCUSSION

Canalicular wounds represent the first cause of intervention in lacrimal traumatology [6]. They are relatively rare, less than 5% of surgical procedures in ophthalmology. They can occur at

any age but more frequently affect children and young adults [7] with male predominance [6].

Direct and frank section wounds are most often caused by fights [6–8]. The left side is affected in 60% of cases [6] and the inferior canaliculus is most frequently affected [8] since the superior canaliculus is better protected by frontal bony projections.

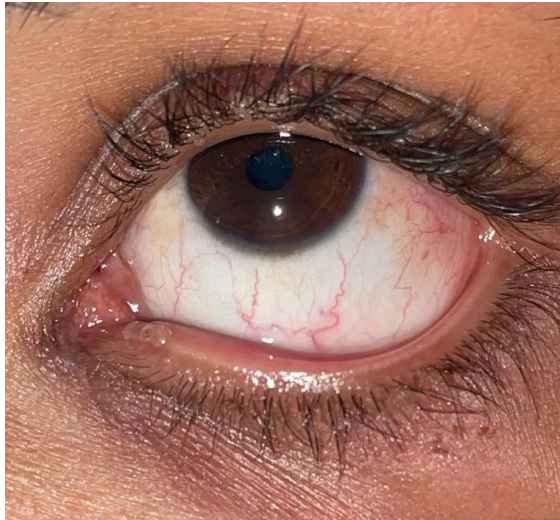

Fig. 5. Appearance at the 4th week of control with good healing of the wound and a fixed and stable flange

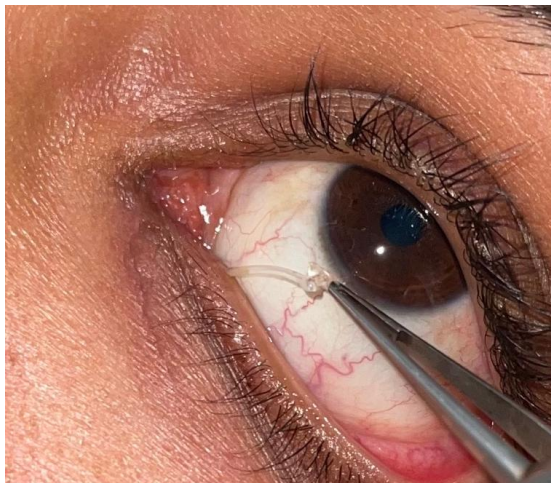

Fig. 6. Removal of the probe under topical anesthesia by simple traction on the flange using forceps. There is no lacrimation, bone contact is present, lacrimal ducts irrigation is permeable

The seat of the anatomical lesion makes it possible to separate lacrimal canalicular wounds into two categories [4–5].

- Wounds of the internal 1/3: It must be certain that the quantity of silicone tube, on each side of the section remains sufficient. In these cases, a complete mono-canaliculo-nasal intubation (MCNI), or a bi-canaliculo-nasal intubation (BCNI) is performed.
- Wounds of the external 2/3: the most common [2–6], where vertical intubation is not essential. In these cases, we perform a true mono-canalicular intubation (IMC) as for our patient.

Canalicular lacerations should preferably be repaired within 72 h of injury before the cut edges heal and epithelize [1]. Once inflammatory edema of the peri-canalicular tissue develops, identification of the internal cut edge and repair becomes difficult. Recently, some authors have suggested that the repair of canalicular tears can be delayed for up to 11 days [9].

Several methods have been described to help identify the medial end of the severed canaliculus (such as injecting air, fluorescein, or viscoelastic substances through the opposite punctum while maintaining pressure on the lacrimal sac and viewing the medial cut area submerged in saline, or the use of a pigtail probe in late presenting patients, which risks damaging the normal canaliculus in inexperienced hands) [1– 2 – 8 – 10 – 11]. We did not need to employ any of these methods because our patient presented 4 hours post trauma and the medial end of the severed canaliculus was identified by its pinkish white appearance and tubular mucosal structure under the operating microscope.

The interest of mono-canalicular intubation with self-stabilizing meatic fixation lies within the limits of other intubation techniques, or to reduce their undesirable effects (extended stricturotomy, irreducible early exteriorization, retention of material in the lacrimal sac at the time of its removal, source of dacryocystitis), while retaining the benefit of intubation [4–5].

Meatic fixation has several advantages over other intubation techniques.

- The head provides sufficient self-stabilizing fixation for the entire probe, without palpebral or intra-canalicular suture, which seemed logical for a short length of silicone tube, but less so for a canaliculo-nasal probe.
- It is not protruding like the inter-palpebral loop of the BCNI and the suture of the

other mono-canalicular tutors. The risk of accidental externalization must decrease.

- The stopper knots are removed, and with them the adjustment in the nasal cavity of the tension of the BCNI. There is no risk of secondary stricturotomy with the mono-canalicular probe.
- Adaptable, it allows the simplest intubation under local anesthesia in adults for each type of wound. For the external 2/3 wounds, the useful length of silicone is cut in the operating field, dispensing with intubation of the vertical segment of the lacrimal excretion ducts.

The canaliculus can be approximated by two to three absorbable 8-0 polyglactin sutures placed in the wall of the cut canaliculus to achieve mucosal apposition [1–7]. Some authors have used a single horizontal peri-canalicular mattress suture (polyglactin 7-0), with anatomical success in 100% of patients [12]. Studies of normal healing suggest that the process of proliferative fibrosis is complete in 3 months [13]. It is therefore preferable to leave the probe in place for at least 12 weeks, before performing the removal, which is easy in the office with forceps under topical anesthesia, even in children.

The functional and anatomical tolerance of mono-canalicular intubation with self-stabilizing meatic fixation has proven to be satisfactory in the literature (rare cases of the internal angle pruritus, canaliculitis, pyogenic granuloma and punctal stenosis have been reported). The main pitfall was intra-canalicular migration (and threat of migration), premature extrusion and unreported or unnoticed ablation losses (especially in children) [1 - 4 - 5 - 7 - 14]. Our patient presented no undesirable effects or complications reported in the literature, with a permeable lower canaliculus after a 5-month follow-up.

4. CONCLUSION

True mono-canalicular intubation, using a flexible mono-canalicular probe with self-stabilizing meatic fixation, has several advantages over other lacrimal intubation techniques.

The placement of this probe is essential, to ensure the correct alignment of the anastomosis and the lacrimal lumen during the healing phase, to prevent fibrosis and stenosis after canalicular repair and thus to maintain permeability [15].

The introduction of this probe has facilitated the repair of mono-canalicular lacerations under local anesthesia, thus avoiding unnecessary manipulations and possible iatrogenic lesions of the healthy canaliculus.

CONSENT

As per international standard or university standard, patient(s) written consent has been collected and preserved by the author(s).

ETHICAL APPROVAL

As per international standard or university standard written ethical approval has been collected and preserved by the author(s).

COMPETING INTERESTS

Authors have declared that no competing interests exist.

REFERENCES

1. Md. Shahid Alam, Neha Shirao Mehta, Bipasha Mukherjee, Anatomical and functional outcomes of canalicular laceration repair with self-retaining mini-MONOKA stent. *Saudi Journal of Ophthalmology*. 2017;31(3):135-139. ISSN 1319-4534. Available:<https://doi.org/10.1016/j.sjopt.2017.04.009>
2. Han J, Chen H, Wang T, Zhang X, Jin X, A case series study of lacrimal canalicular laceration repair with the bi-canalicular stent. *Gland Surgery, North America*, Vol 11, N°11; 2022. Available:<https://gs.amegroups.com/article/view/104554>
3. Singh S, Ganguly A, Hardas A, Tripathy D, Rath S, Canalicular lacerations: Factors predicting outcome at a tertiary eye care centre. *Orbit*. 2017;36(1):13-18.
4. Fayet B, Bernard JA, Pouliquen Y. A self-stabilizing meatic fixation mono-canalicular probe for lacrimal duct repair. *Bull Soc Oph Fr*. 1989;6-7:819-25.
5. Fayet B, Bernard JA. A monocanalicular stent with self-stabilizing meatic fixation in surgery of excretory lacrimal ducts. Initial results. *Ophtalmologie*. 1990;4:351-357.
6. El khaoua M, et al. Injuries of lachrymal ducts: regarding 72 cases. *JSMO*. 2016;5. Available:<https://doi.org/10.48400/IMIST.PRSM/JSMO/8900>

7. Mehmet Serhat, Mangan Sevil Gul Turan, Serap Yurttaser Ocak. Pediatric canaliculalaceration repair using the Mini Monoka versus Masterka monocanalicular stent. *Arquivos Brasileiros de Oftalmologia*. 2023;86(1):. Available:<https://doi.org/10.5935/0004-2749.20220084>
8. Chun-Hsien Lin, Chun-Yuan Wang, Ying-Cheng Shen, Li-Chen Wei. Clinical characteristics, intraoperative findings, and surgical outcomes of canaliculalaceration repair with monocanalicular stent in Asia. *Journal of Ophthalmology*. 2019; 2019:6, Article ID 5872485. Available:<https://doi.org/10.1155/2019/5872485>
9. Mukherjee B, Dhobekar M. Management of Lacrimal System Trauma. In: Mukherjee B, Yuen H, (eds) *Emergencies of the Orbit and Adnexa*. Springer, New Delhi; 2017. Available:https://doi.org/10.1007/978-81-322-1807-4_12
10. Örgüç FH, Dar SA. Canaliculalaceration repair using a viscoelastic injection to locate and dilate the proximal torn edge. *J AAPOS*. 2015;19:217-9. [Crossref] [PubMed].
11. Yimin Li, Yefei Wang, Lunhao Li, Caiwen Xiao, Xiaoping Bi, Huifang Chen, Wodong Shi. Long-term outcomes of a new anatomy-based method for finding the medial cut end during late canaliculalaceration repair. *Journal of Plastic, Reconstructive & Aesthetic Surgery*. 2023;76:96-104: ISSN 1748-6815. Available:<https://doi.org/10.1016/j.bjps.2022.10.005>
12. Kersten RC, Kulwin DR. One stitch” canaliculalaceration repair: A simplified approach for repair of canaliculalaceration. *Ophthalmology*. 1996;103:785-789.
13. Leibovitch I, Kakizaki H, Prabhakaran V, Selva D, Canaliculalacerations: Repair with the Mini-Monoka® monocanalicular intubation stent. *Ophthalmic Surg Lasers Imaging*. 2010;41(4):472-7. DOI: 10.3928/15428877-20100525-05 Epub 2010 May 28. PMID: 20608616
14. Kim T, Yeo CH, Chung KJ, Lee JH, and Kim YH. Repair of lower canaliculalaceration using the Mini-Monoka stent. *Journal of Craniofacial Surgery*. 2018;29(4):949–952,
15. Al-Battashy Aisha, Al-Mujaini Abdullah S. Canaliculalacerations: Techniques used and timing to intervene. *Oman Journal of Ophthalmology*. 2023;16(2): 201-204. DOI: 10.4103/ojo.ojo_101_23

© 2023 El Mhadi and El Ouafi; This is an Open Access article distributed under the terms of the Creative Commons Attribution License (<http://creativecommons.org/licenses/by/4.0>), which permits unrestricted use, distribution, and reproduction in any medium, provided the original work is properly cited.

Peer-review history:

The peer review history for this paper can be accessed here:
<https://www.sdiarticle5.com/review-history/104971>