

Evaluation of Posterior Tibial Slope for Anterior Cruciate Ligament Tear and Meniscal Tear: A Cross-sectional Study

SATHYA SABINA MUTHU¹, U SHRIKRISHNA², KAYALVIZHI RAVICHANDRAN³

ABSTRACT

Introduction: The Posterior Tibial Slope (PTS) is an angle formed by the tibial plateau and supports the biomechanics of the knee joint. This slope is found to be a factor in differentiating ACL tear injuries. Earlier studies have shown the association of PTS with Anterior Cruciate Ligament (ACL) tears, but have not evaluated the PTS values for different gradings.

Aim: To evaluate the PTS on X-ray and Magnetic Resonance Imaging (MRI), for patients with different grades of ACL tears, and patients identified with meniscal tears.

Materials and Methods: This cross-sectional study was conducted from April 2020 to March 2021 at the Department of Radiodiagnosis and Imaging, KS Hegde hospital, Mangaluru, Karnataka, India. A total of 30 patients were studied, in which 20 patients with ACL tears underwent both X-ray and MRI, while the 10 patients with meniscal tears were only subjected to MRI. The PTS was evaluated for different grades of ACL tears on X-ray and MRI by an experienced Radiologist. The number of patients with grade I, grade II, and grade III ACL tears were 7, 6 and 7, respectively. Paired t-test was used to evaluate the mean PTS for the identified grade of the ACL tear. One-way Analysis of Variance (ANOVA) and Bonferroni's post-hoc test was used to analyse the difference between grades of the ACL tear.

Results: The mean age of the study population was 32.50 ± 16.363 years, and the male-to-female ratio was 4:1. Both right, as well as the left knee, were included in the study, and the left-to-right knee ratio was 3:2. There was a significant difference in PTS between Grades of ACL tears (p -value=0.001). The PTS was observed to increase as the severity of the ACL injury increased. The mean PTS value obtained on X-ray for grade I, grade II, and grade III ACL tears were 10.85 ± 0.54 , 14.18 ± 0.62 , and 16.46 ± 1.56 , respectively. While the mean PTS value obtained on MRI for grade I, grade II, and grade III ACL tears were 10.85 ± 0.53 , 14.19 ± 0.60 , and 16.47 ± 1.55 , respectively. There was no significant difference in the PTS measured for ACL tears between the X-ray and MRI (p -value >0.05). Further, the results did not show any difference of significance in the PTS measured on MRI between ACL tears and meniscal tears (p -value >0.05).

Conclusion: The PTS can be used as an aid in the identification of the severity of the ACL injury. The PTS could also be used as a tool to recognise the presence of ACL tears on X-ray and this could be an important prognostic factor towards the functional outcome.

Keywords: Knee joint, Magnetic resonance imaging, X-rays

INTRODUCTION

The day-to-day activities of everyday life are largely dependent on the lower limb. The knee joint, being a type of complex hinge joint in the body supports the various activities of everyday life. It has a vital role in weight-bearing and maintaining the position, whether standing or moving [1]. The knee joint can be considered as two joints, a tibiofemoral joint, and a patellofemoral joint. The tibiofemoral joint is responsible for transmitting the weight of the body from the femur to the tibia and provides a hinge-like sagittal plane joint rotation accompanied by a small degree of tibial axial rotation [2]. On the other hand, the primary function of the patellae is to act as a mechanical pulley for the quadriceps, when the patellae go through a change in the direction of the extension force throughout the knee range of motion [3]. The knee joint has various ligaments that provide stability to the joint. The ligaments and menisci are often injured during heavy activities that cause strain to the knee joint. Early diagnosis and treatment are essential to prevent disability of the knee joint.

The articular surface of the tibial plateau forms posterior and inferior slopes about the longitudinal axis of an axial center and is known as the Posterior Tibial Slope (PTS) [4]. This slope is found to vary in different studies according to age, gender, and ethnicity [5,6]. The Posterior Tibial Slope (PTS) is measured to assess its relationship to tibial translation, knee joint stability, and Anterior Cruciate Ligament (ACL) injuries [7]. The knee biomechanics is largely affected by the

Posterior Tibial Slope (PTS). The PTS is considered an indicator of ACL tears [5]. Studies have shown that individuals with ACL injuries have a greater PTS than individuals with normal ACL [8-10]. In addition, PTS plays an important role in the planning of surgical interventions such as tibial osteotomy, tibial osteoarthritis, and knee arthroplasty [4].

Many studies have proved that PTS can be a factor that influences the incidence of ACL tears [6,9,11]. But to the best of authors' knowledge, none of the earlier performed studies has evaluated the PTS for different Grades of ACL tears. Hence, the present study would be a pioneer that has investigated the PTS for different grades of ACL tears on X-ray and MRI. This knowledge about PTS would improve the outcome of ACL tear treatment as PTS is a factor that influences the biomechanics of the knee.

The present study has focussed on evaluating the measurements of the PTS for different grades of ACL tears on X-ray and Magnetic Resonance Imaging (MRI). Furthermore, the gender difference in PTS for ACL tears was evaluated and PTS for meniscal injuries was assessed, and compared it with the PTS, measured for ACL injuries.

MATERIALS AND METHODS

A cross-sectional study was conducted in the Department of Radiodiagnosis and Imaging at KS Hegde hospital, Mangaluru, Karnataka, India, from April 2020 to March 2021. The study was initiated after obtaining ethical clearance from the Institutional Ethical

Clearance Committee (INST.EC/044/2020-21). Informed written consent was obtained from the subjects included in the study. The patients with a history of knee pain or trauma were referred to the Department of Radiodiagnosis for performing an X-ray or MRI examination of the knee within the stipulated period of study duration from the sample population.

Inclusion and Exclusion criteria: The patients who had an X-ray and MRI performed of the same knee joint, within the age group of 18-60 years with ACL or meniscal tears were included in the study. The patients with a previous history of knee surgery, anatomical variations in the tibia, and other knee pathology were excluded from the study based on X-ray and MRI reports.

The PTS values needed for the study were measured prospectively on 30 samples diagnosed with ACL or meniscal tear. The ACL tears were classified into three grades as follows [8]:

Grade I- Mild tear with the ACL fibres being intact and less than 10% of fibres torn,

Grade II- Partial tear with the ACL fibres being stretched and 10-50% of fibres torn,

Grade III- Complete tear with the ACL fibres being separated into two parts and more than 50% of fibres torn.

Study Procedure

The X-ray of the affected knee joint was performed using the digital radiography Agfa DX- D 600 system. A true lateral view was obtained of the knee under examination. The patient was positioned on the affected side with 45° flexion of the knee and sand bags were used to achieve adequate positioning of the patient. The X-ray image obtained was transferred to the PACS system where the measurements were conducted. The PTS was measured by considering the Proximal Tibial Anatomical Axis (PTAA). A reference line was drawn perpendicular to this tibial axis and a line tangent to the tibial plateau was drawn and the angle between the tangent and reference line was measured as the slope angle [Table/Fig-1].

The MRI examination of the same knee as referred by the Orthopaedic Department was conducted. The MRI study was performed on Siemens MAGNETOM Avanto 1.5 Tesla system. The study was initiated after ensuring that there were no metallic objects in the patient's body, which is a major contraindication of MRI. The patient was placed supine with a feet-first orientation. The dedicated knee coil was placed over the knee joint under study. The study was performed by choosing the routine MRI knee protocol that consists of axial PDFS, coronal T1W, coronal T2W, coronal PDF, sagittal T2W, sagittal T1W, sagittal PDFS, and, axial T2W images. The diagnosis was performed by the radiologist of the Department of Radiodiagnosis and Imaging.

A single radiologist with more than 20 years of experience assessed both the X-ray as well as the MRI of the same knee. The patients identified with ACL injuries or meniscal injuries were

selected as study samples and the images of these patients were transferred to the PACS system where the PTS measurements were conducted. The sagittal plane was chosen as the image of interest for evaluating the PTS on MRI. First, the MRI-longitudinal axis of the tibia was recognised by finding the MRI slice that exhibited the Posterior Cruciate Ligament (PCL) attachment and the intercondylar eminence. Then, the lateral plateau was identified and a tangent to it was drawn, and also a reference line perpendicular to the longitudinal axis was drawn. The PTS was then measured as the angle between the tangent and the reference line [Table/Fig-2]. The PTS was measured for different grades of ACL tear on X-ray and MRI [Table/Fig-3].

STATISTICAL ANALYSIS

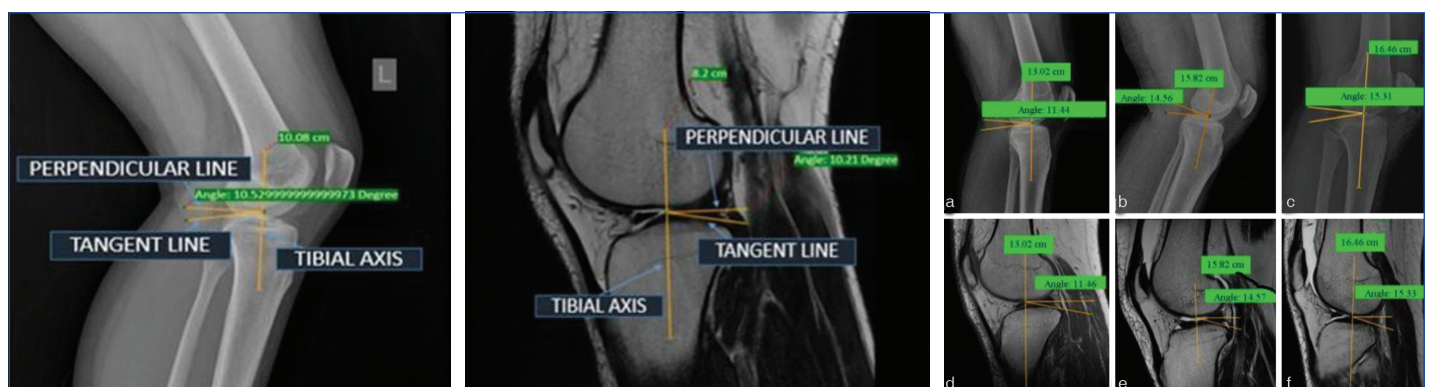
The collected data were analysed using the Statistical Package for Social Sciences (SPSS) version 20.0 software. Paired t-test was used to evaluate the mean PTS for the identified grade of the ACL tear. One-way Analysis of Variance (ANOVA) and Bonferroni's post-hoc test was used to analyse the difference between grades of the ACL tear. While, unpaired t-test was used to assess the PTS in males and females with ACL rupture and to compare the PTS data on X-ray with MRI for an ACL tear. The assessment of meniscal tear average values and its comparison with the PTS of ACL was performed using an unpaired t-test.

RESULTS

There were 20 patients identified with an ACL tear and had a mean age of 32.50 ± 16.363 years. The number of male patients was 16 (80%) and the number of female patients was 4 (20%) with ACL injury (male-to-female ratio was 4:1). The study included 12 left knee cases (60%) and 8 (40%) right knee cases. There were 10 patients with a mean age of 32.9 ± 14.185 years with meniscal tears out of which five patients had a tear in the lateral meniscus and five patients had a tear in the medial meniscus. Both right, as well as the left knee, were included in the study, and the left-to-right knee ratio was 3:2.

The analysis for grade I ACL tear revealed no significant difference observed on X-ray and MRI for grade I ACL tear (p -value >0.05). The PTS observed did not differ significantly for grade II ACL tears on X-ray and MRI (p -value >0.05). The PTS data evaluation for grade III ACL tear showed no significant difference observed on X-ray and MRI for grade III ACL tear (p -value >0.05) [Table/Fig-4]. The PTS for all grades of ACL tears in the results of the study was evaluated to be 13.81 ± 2.61 on MRI and 13.83 ± 2.70 on X-ray.

The results showed a significant difference in PTS on X-ray and also on MRI for intergrading analysis of ACL tear with p -value <0.05 [Table/Fig-5]. There was no significant difference in PTS between males and females found with ACL tears (p -value >0.05) [Table/Fig-6]. There was no significant difference in PTS between medial



[Table/Fig-1]: PTS measurement on X-ray (lateral view). **[Table/Fig-2]:** PTS measurement on MRI (sagittal plane). **[Table/Fig-3]:** Posterior Tibial slope measurements for different grades of ACL tear. (Images from left to right) [Table/Fig-3] A and D shows the measurements of PTS for Grade I ACL tear on X-ray and MRI, B and E shows the measurements of PTS for Grade II ACL tear on X-ray and MRI, C and F shows the measurements of PTS for Grade III ACL tear on X-ray and MRI

Group		N	Mean±SD	Paired t-test	p-value
Grade I	PTS on X-ray	7	10.8500±0.54397	-0.956	0.376
	PTS on MRI	7	10.8571±0.53925		
Grade II	PTS on X-ray	6	14.1867±0.62173	-0.378	0.721
	PTS on MRI	6	14.1900±0.60610		
Grade III	PTS on X-ray	7	16.4657±1.56255	-1.072	0.325
	PTS on MRI	7	16.4743±1.55432		

[Table/Fig-4]: Posterior tibial slope for grade I, grade II and grade III ACL tear.

meniscus tear and lateral meniscus tear cases (p -value >0.05) [Table/Fig-7]. The PTS on MRI for ACL tear was observed to be 13.8230 ± 2.61236 and for meniscal tear, it was observed to be 14.9250 ± 1.89736 . There was no significant difference in PTS between ACL tear and meniscal tear (p -value >0.05) [Table/Fig-8].

Dependent variable	(I) ACL tear grade	(J) ACL tear grade	Mean difference (I-J)	p-value	95% Confidence interval	
					Lower bound	Upper bound
Posterior tibial slope on X-ray	1	2	-3.33667	0.001	-4.8716	-1.8017
		3	-5.61571	0.001	-7.0904	-4.1410
	2	3	-2.27905	0.003	-3.8140	-0.7441
Posterior tibial slope on MRI	1	2	-3.33286	0.001	-4.8560	-1.8097
		3	-5.61714	0.001	-7.0806	-4.1537
	2	3	-2.28429	0.003	-3.8075	-0.7611

[Table/Fig-5]: Analysis of posterior tibial slope for an intergrading ACL tear. One-way ANOVA and Bonferroni's post-hoc tests were used in analysing the difference between grades of an ACL tear

Posterior tibial slope	Sex	N	Mean±SD	Unpaired t-test	p-value
On X-ray	M	16	14.1881±2.72198	1.294	0.212
	F	4	12.3300±1.60447		
On MRI	M	16	14.1938±2.71945	1.292	0.213
	F	4	12.3400±1.60591		

[Table/Fig-6]: Posterior tibial slope variation in sex for ACL tear patients.

Posterior tibial slope on MRI	N	Mean±SD	Unpaired t-test	p-value
Medial meniscus	5	14.7980±1.41920	-0.200	0.846
Lateral meniscus	5	15.0520±2.45876		

[Table/Fig-7]: Posterior tibial slope for medial and lateral meniscal tear.

Posterior tibial slope on MRI	N	Mean±SD	Unpaired t-test	p-value
ACL tear	20	13.8230±2.61236	-1.183	0.247
Meniscal tear	10	14.9250±1.89736		

[Table/Fig-8]: Comparison of posterior tibial slope between ACL tear and meniscal tear.

DISCUSSION

One of the most frequently affected structures of the knee joint is the ACL and the meniscus. These are vital small structures of the complex knee joint that help in maintaining the stability of the joint. These structures mostly get injured during some traumatic non contact events. A factor that has been observed to be associated with ACL tears is the PTS. It is an angle formed anteroposteriorly by the tibial plateau in line, with its longitudinal axis [2].

The study by Priono BH et al., revealed the PTS to be greater in ACL tear cases with an angle of 14.5 ± 3.5 [11]. The study performed by Todd MS et al., evaluated the relationship of PTS with ACL injuries on X-ray film and found the PTS to be higher in ACL injuries. The PTS in their study for ACL tears was 9.39 ± 2.58 [12]. And the investigation by Kumar R and Kunal K showed the PTS to be 13.037 ± 4.487 in the study group with ACL tears [13]. The PTS observed in this study

for ACL tears was quite similar to the results of Priono BH et al., and Kumar R and Kunal K [12,13].

Hudek R et al., in their study of evaluating the PTS on X-ray and MRI, found a difference in the PTS measured between X-ray and MRI of the same knee [10]. Whereas, the results in the present study did not show any significant difference in PTS on X-ray and MRI of the identical knee. As per the present study, the PTS measured on MRI is reproducible on X-ray for different grades of ACL tears. This reproducibility could be used to identify the grades of ACL tears on X-ray by measuring the PTS. The values measured could guide in identifying the grades on X-ray as the current study results showed the least PTS value for grade I ACL tear and the highest value for grade III ACL tear.

In the study performed by DePhillipo NN et al., and Panigrahi TK et al., the PTS values were not observed to differ significantly between males and females with ACL ruptures [9,14]. The observations in the present study were also similar to theirs as there was no difference of significance noted in PTS between males and females with ACL tears. This lack of significant difference in the present analysis could have occurred due to the unequal sample distribution that included 80% male cases and only 20% female cases. Similar gender distribution was observed in the study performed by Kumar R and Kunal K, which had 90% ACL tears in males and only 5% female cases with ACL injuries [13].

The investigation performed by Alici T et al., concerning the association of PTS and meniscal injury demonstrated that the PTS for the group with lateral meniscus injury was higher compared to the group with medial meniscus injury [15]. The observations in the present study were also similar as the mean PTS for knees with lateral meniscus tears was greater than the knees with a medial meniscus tear. However, the difference observed between medial and lateral meniscus tears was not significant in the present study (p -value >0.05). The present study also attempted to compare the PTS obtained for ACL tear cases with the PTS obtained for meniscus tears, but the analysis showed no significant difference. The lack of significance in the present study could have occurred due to the lesser number of samples included with meniscal injuries, than those with ACL tears.

The measurements of PTS were conducted by a single observer on all the images in the present study but the other investigations like the one performed by Kacmaz IE et al., have conducted the measurements by more than one observer and computed the data [16]. As a future scope, the present study could be beneficial in identifying and recognising the severity of ACL tears present standard method of grading ACL tears. The additional MRI studies could be avoided in suspected cases of ACL tears by evaluating the PTS on X-ray and this would limit the cost as MRI is more expensive than X-ray. The knowledge of PTS, could also serve as a guiding factor in the surgical procedures of the knee joint.

Limitation(s)

Small sample size and shorter duration are the main limitations of the study. The PTS for different categories of meniscal tears were not analysed in the present study and could be performed as a future investigation. The study did not analyse the PTS separately, for the medial and lateral plateau of the tibia in the present study and could be studied in the future.

CONCLUSION(S)

The significant difference in PTS obtained among the different grades of ACL tears could aid in the identification of the severity of the ACL injury. The PTS could also be used as a tool to recognise the presence of ACL tears on X-ray and this could be an important prognostic factor, towards the functional outcome.

REFERENCES

- [1] Karimi E, Norouzi M, Birjandinejad A, Zandi R, Makhmalbaf H. Measurement of posterior tibial slope using magnetic resonance imaging. *Arch Bone Jt Surg.* 2017;5(6):435-39.
- [2] Flandry F. Normal anatomy and biomechanics of the knee. *Sports Med Arthrosc Rev.* 2011;19(2):11.
- [3] Loudon JK. Biomechanics and pathomechanics of the patellofemoral joint. *Int J Sports Phys Ther.* 2016;11(6):820-30.
- [4] Nekkanti S, Patted P, Nair L, Chandru V, Shashank G. The variation of the posterior tibial slope in South Indians: A hospital-based study of 290 cases. *Niger J Orthop Trauma.* 2018;17(1):17.
- [5] Weinberg DS, Williamson DFK, Gebhart JJ, Knapik DM, Voos JE. Differences in medial and lateral posterior tibial slope: An osteological review of 1090 tibiae comparing age, sex, and race. *Am J Sports Med.* 2017;45(1):106-13.
- [6] Sun YH, Chen LX, Jiao ZD, Wang L, Zhang RM, Fang J, et al. Age-related changes of posterior tibial slope and its roles in anterior cruciate ligament injury. *Int Surg.* 2016;101(1):70-77.
- [7] Pangaud C, Laumonerie P, Dagneaux L, LiArno S, Wellings P, Faizan A, et al. Measurement of the posterior tibial slope depends on ethnicity, sex, and lower limb alignment: A computed tomography analysis of 378 healthy participants. *Orthop J Sports Med.* 2020;8(1):232596711989525.
- [8] Ng CK, Griffith JF, Hung EHY, Paunipagar B, Law BK, Yung PSH, et al. Imaging of the anterior cruciate ligament. *World J Orthop.* 2011;2(8):75-84.
- [9] Panigrahi TK, Das A, Mohanty T, Samanta S, Kumar Mohapatra S. Study of the relationship of posterior tibial slope in anterior cruciate ligament injury. *J Orthop.* 2020;21:487-90.
- [10] Hudek R, Schmutz S, Regenfelder F, Fuchs B, Koch PP. Novel measurement technique of the tibial slope on conventional MRI. *Clin Orthop.* 2009;467(8):2066-72.
- [11] Priono BH, Utoyo GA, Ismiarto YD. Relationship of ACL injury with Posterior Tibial Slope, Intercondylar notch width ratio, age, and sex. *J Orthop Traumatol Surabaya.* 2018;7(2):10613.
- [12] Todd MS, Lalliss S, Garcia E, DeBerardino TM, Cameron KL. The relationship between posterior tibial slope and anterior cruciate ligament injuries. *Am J Sports Med.* 2010;38(1):63-67.
- [13] Kumar R, Kunal K. Radiographic evaluation of posterior tibial slope in ACL deficient Indian patients. *Int J Res Orthop.* 2019;5(3):473.
- [14] DePhillipo NN, Zeigler CG, Dekker TJ, Grantham WJ, Aman ZS, Kennedy MI, et al. Lateral posterior tibial slope in male and female athletes sustaining contact versus noncontact anterior cruciate ligament tears a prospective study. *Am J Sports Med.* 2019;47(8):1825-30.
- [15] Alici T, Esenyel CZ, Esenyel M, Imren Y, Ayanoglu S, Cubuk R, et al. Relationship between meniscal tears and tibial slope on the tibial plateau. *Eurasian J Med.* 2011;42(3):146-51.
- [16] Kacmaz IE, Topkaya Y, Basa CD, Zhamilov V, Er A, Reisoglu A, et al. Posterior tibial slope of the knee measured on X-rays in a Turkish population. *Surg Radiol Anat.* 2020;42(6):673-79.

PARTICULARS OF CONTRIBUTORS:

1. Lecturer, Department of Radiology, Amar Shanth Paramedical Institute, Tejasvini Hospital Group of Institutions, Mangaluru, Karnataka, India.
2. Professor, Department of Radiodiagnosis and Imaging, KS Hegde Medical Academy, Nitte Deemed to be University, Mangaluru, Karnataka, India.
3. Assistant Professor, Department of Radiodiagnosis and Imaging, KS Hegde Medical Academy, Nitte Deemed to be University, Mangaluru, Karnataka, India.

NAME, ADDRESS, E-MAIL ID OF THE CORRESPONDING AUTHOR:

Dr. Kayalvizhi Ravichandran,
Assistant Professor, Department of Radiodiagnosis and Imaging, KS Hegde
Medical Academy, Nitte Deemed to be University, Mangaluru, Karnataka, India.
E-mail: kayalravi3@gmail.com

PLAGIARISM CHECKING METHODS: [Jain H et al.]

- Plagiarism X-checker: Jun 30, 2022
- Manual Googling: Oct 26, 2022
- iThenticate Software: Oct 31, 2022 (17%)

ETYMOLOGY: Author Origin

AUTHOR DECLARATION:

- Financial or Other Competing Interests: None
- Was Ethics Committee Approval obtained for this study? Yes
- Was informed consent obtained from the subjects involved in the study? Yes
- For any images presented appropriate consent has been obtained from the subjects. Yes

Date of Submission: **Jun 28, 2022**

Date of Peer Review: **Sep 16, 2022**

Date of Acceptance: **Nov 01, 2022**

Date of Publishing: **Jan 01, 2023**